BIO 113 LAB 1. Anatomical Terminology, Positions, Planes, and Sections and more

Objectives

- Describe the anatomical position verbally or by demonstrating it
- Demonstrate ability to use anatomical terms describing body landmarks, directions, planes, and surfaces.
- Name the body cavities, and indicate important organs in each cavity.
- Understand serial sections and anatomical reconstruction

Most of us are naturally curious about our bodies. This curiosity is apparent even in infants, when they gaze in fascination at their own waving hands or their mother's nose. Unlike the infant, however, an anatomy student must learn to identify body structures formally.
This exercise presents some of the most important anatomical terms you will be using to describe the body and introduces you to gross anatomy, the study of body structures you can see with your naked eye. As you become familiar with this anatomical terminology, you will have a chance to examine the three-dimensional relationships of body structures using illustrations and models.

Proper Anatomical Position
When doctors refer to specific areas of the human body, they do so relative to a standard position called the anatomical position. In the anatomical position, the human body is erect, with head and toes pointed forward and arms hanging at the sides with palms facing forward (see Figure 3).

Demonstrating the Anatomical Position
Stand, and assume the anatomical position. Notice that it is not particularly comfortable, because you must hold your hands unnaturally forward instead of allowing them to hang partially cupped toward your thighs.

Surface Anatomy
Body surfaces provide a number of visible landmarks that can be used to study the body. Several of these are described on the following pages.

Locating Body Landmarks

Anterior Body Landmarks
Identify and use anatomical terms to correctly label the following regions on Figure 1:

Abdominal: The anterior body trunk region inferior to the ribs
Antecubital: The anterior surface of the elbow
Axillary: The armpit
Brachial: The arm
Buccal: The cheek
Carpal: The wrist
Cervical: The neck region
Coxal: The hip
Deltoid: The roundness of the shoulder caused by the underlying deltoid muscle
Digital: The fingers or toes
Femoral: The thigh
Fibular: The side of the leg
Inguinal: The groin
Mammary: The breast
Manus: The hand
Nasal: The nose
Oral: The mouth
Orbital: The bony eye socket (orbit)
Patellar: The anterior knee (kneecap) region
Pelvic: The pelvis region
Pubic: The genital region
Sternal: The region of the breastbone
Tarsal: The ankle
Thoracic: The chest
Umbilical: The navel

Posterior Body Landmarks

Identify and appropriately label the following body surface regions in Figure 1 b:
Cephalic: The head
Gluteal: The buttocks or rump
Lumbar: The area of the back between the ribs and hips; the loin
Occipital: The posterior aspect of the head or base of the skull
Popliteal: The back of the knee
Sacral: The area between the hips
Scapular: The scapula or shoulder blade area
Sural: The calf or posterior surface of the leg
Vertebral: The area of the spinal column

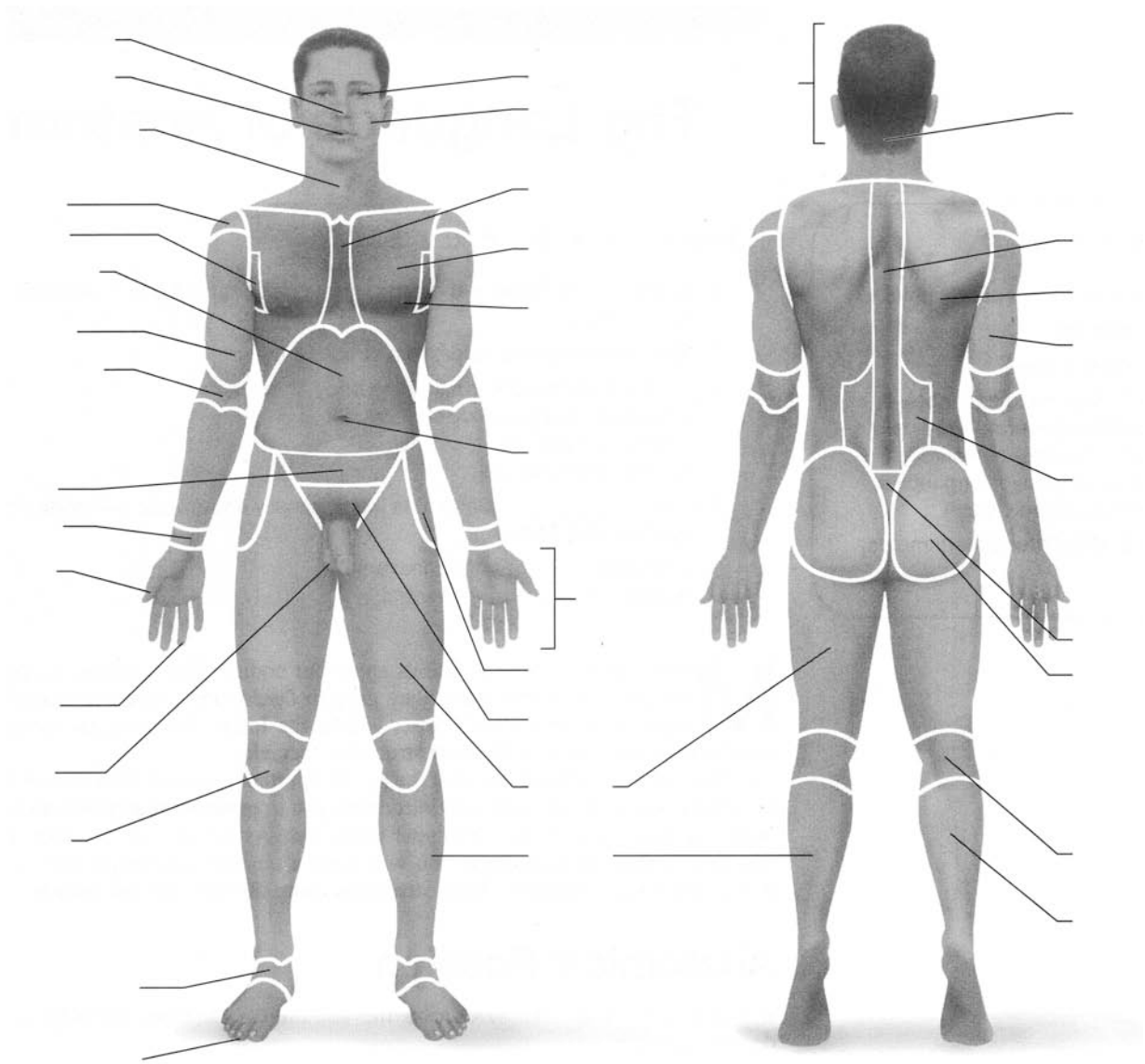

Figure 1. Surface Anatomy. Left image is anterior, Right image is posterior

Body Orientation and Direction

Study the terms below, referring to Figure 2. Notice as you read that certain terms have a different meaning for a four-legged animal than they do for a human.

Superior/inferior *(above/below):* These terms refer to the location of a structure along the long axis of the body. Superior structures appear above other structures, and inferior structures are always below other body parts.

Anterior/posterior *(frontlback):* In humans the most anterior structures are those that are most forward-the face, chest, and abdomen. Posterior structures are those toward the backside of the body.

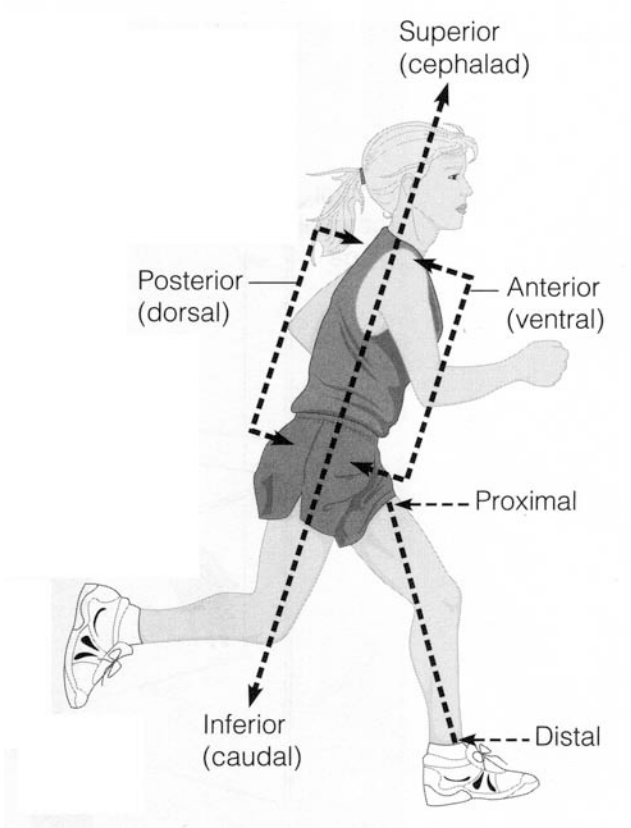

Medial/lateral *(toward the midline/away from the midline or median plane):* Medial structures are closer to the body midline than are lateral structures.

The terms described above assume the person is in the anatomical position. The next four pairs of terms are more absolute. They do not relate to a particular body position, and they have the same meaning in all vertebrate animals.

Cephalad/caudad (caudal) *(toward the head/toward the tail):* In humans these terms are used interchangeably with *superior* and *inferior.* But in four-legged animals, they are synonyms of *anterior* and *posterior,* respectively.

Figure 2. Anatomical terminology for orientation and direction

Dorsal/ventral *(backsidelbelly side):* Meaning "back," the term *dorsal* refers to the animal's back or the *backside* of any other structures. The term *ventral,* meaning "belly," always refers to the belly side of animals. In humans the terms *ventral* and *dorsal* are used interchangeably with the terms *anterior* and *posterior,* but in four-legged animals *ventral* and *dorsal* mean *inferior* and *superior,* respectively.

Proximal/distal *(nearer the trunk or attached end/farther from the trunk or point of attachment):* These terms locate various areas along the body limbs or an elongated organ such as the intestine. For example, the fingers are distal to the elbow; the knee is proximal to the toes.

Superficial/deep *(toward or at the body surface/away from the body surface or more internal):* These terms locate body organs according to their relative closeness to the body surface. For example, the skin is superficial to the skeletal muscles.

Practice Using Correct Anatomical Terminology

Before continuing, use a human torso model, a skeleton, or your own body to specify the relationship between the following structures.

1. The wrist is _____ to the hand.
2. The trachea (windpipe) is _____ to the spine.

3. The brain is _____ to the spinal cord.
4. The kidneys are _____ to the liver.
5. The nose is to _____ the cheekbones.
6. The chest is _____ to the abdomen.
7. The skin is _____ to the skeleton.

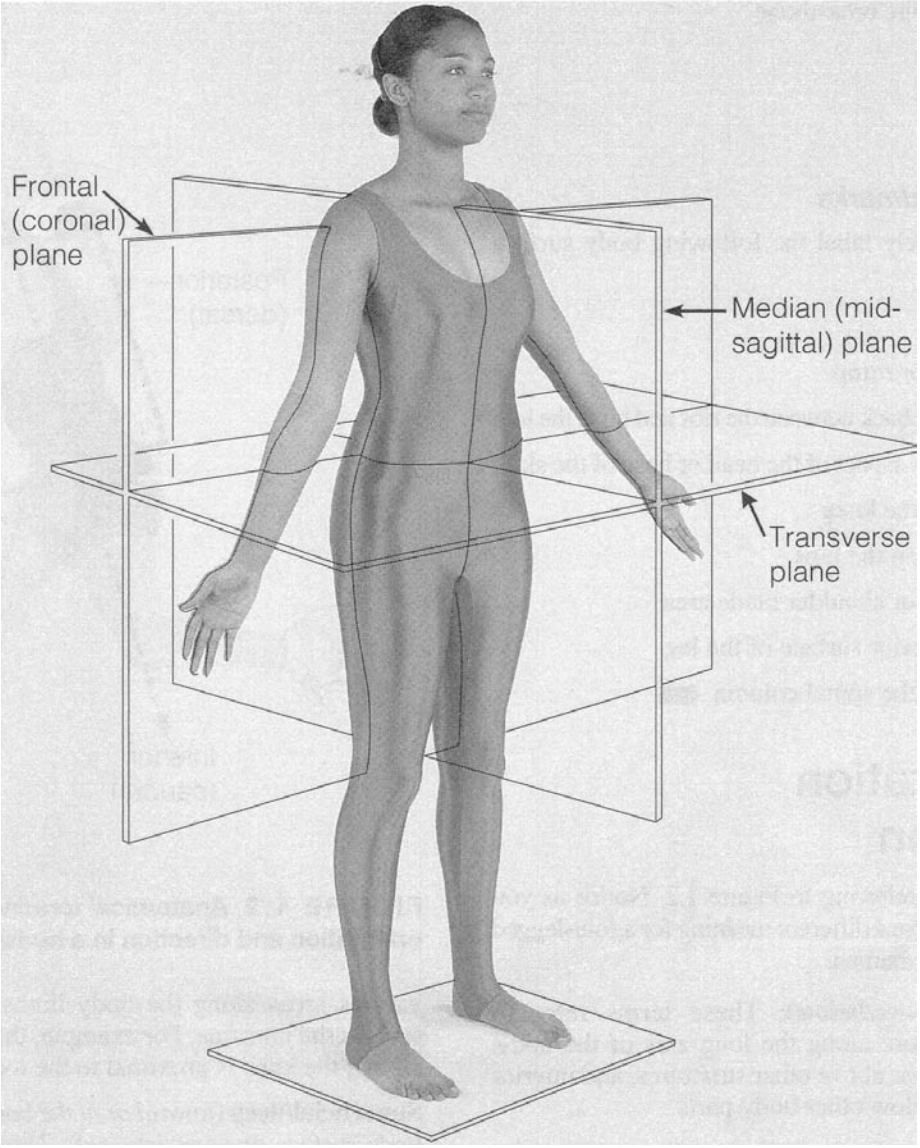

Figure 3. Planes of the body

Body Planes and Sections

The body is three-dimensional. So, to observe its internal parts, it often helps to make use of a section, or cut made along an imaginary surface or line called a plane. There are three planes (Figure 3), or sections, that lie at right angles to one another.

Sagittal plane: A plane that runs lengthwise or longitudinally down the length of the body, dividing it into right and left parts, is a sagittal plane. If it divides the body into equal parts, down the midline of the body, it is called a median, or midsagittal, plane.

Frontal (coronal) plane: A longitudinal plane that divides the body (or an organ) into anterior and posterior parts.

Transverse plane: A plane that runs horizontally, dividing the body into superior and inferior parts. These sections are also commonly called cross sections.

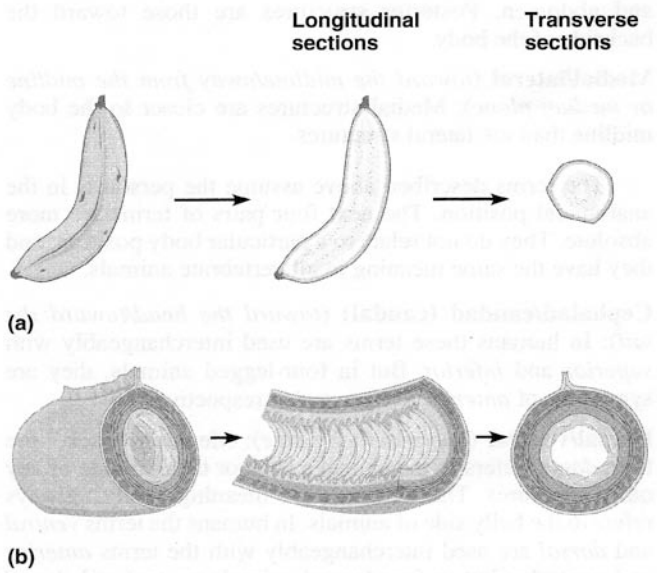

Figure 4. Longitudial and transverse sections

As shown in Figure 4, a sagittal or frontal section of any nonspherical object, be it a banana or a body organ, provides quite a different view from a transverse section.

Observing Sectioned Specimens

1. Observe an entire (uncut) kidney and transversely and longitudinally cut kidneys. Pay close attention to the different structural details you can see in the samples.

2. Observe a sectioned gelatin-spaghetti mold (cooked spaghetti added to warm gelatin that is then allowed to gel.) You should see spaghetti strands that have been cut transversely (XS), longitudinally, and obliquely. Draw each of these spaghetti sections below.

Body Cavities

The axial portion of the body has two main cavities (Figure 5).

Dorsal Body Cavity

The dorsal body cavity consists of the cranial and spinal cavities. The cranial cavity, within the rigid skull, contains the brain. The spinal cavity, which runs within the bony vertebral column, protects the spinal cord. The spinal cord is a continuation of the brain, and the cavities containing them are continuous with each other.

Ventral Body Cavity
Like the dorsal cavity, the ventral body cavity is subdivided. The superior **thoracic cavity** is separated from the rest of the ventral cavity by the muscular diaphragm. The heart and lungs, located in the thoracic cavity, are protected by the bony rib cage. The cavity inferior to the diaphragm is the **abdominopelvic cavity.** Although there is no further physical separation of this part of the ventral cavity, some describe the abdominopelvic cavity in terms of a superior **abdominal cavity**, the area that houses the stomach, intestines, liver, and other organs, and an inferior **pelvic cavity**, which is partially enclosed by the bony pelvis and contains the reproductive organs, bladder, and rectum. Notice that the pelvic cavity tips away from the abdominal cavity in a posterior direction (Figure 5).

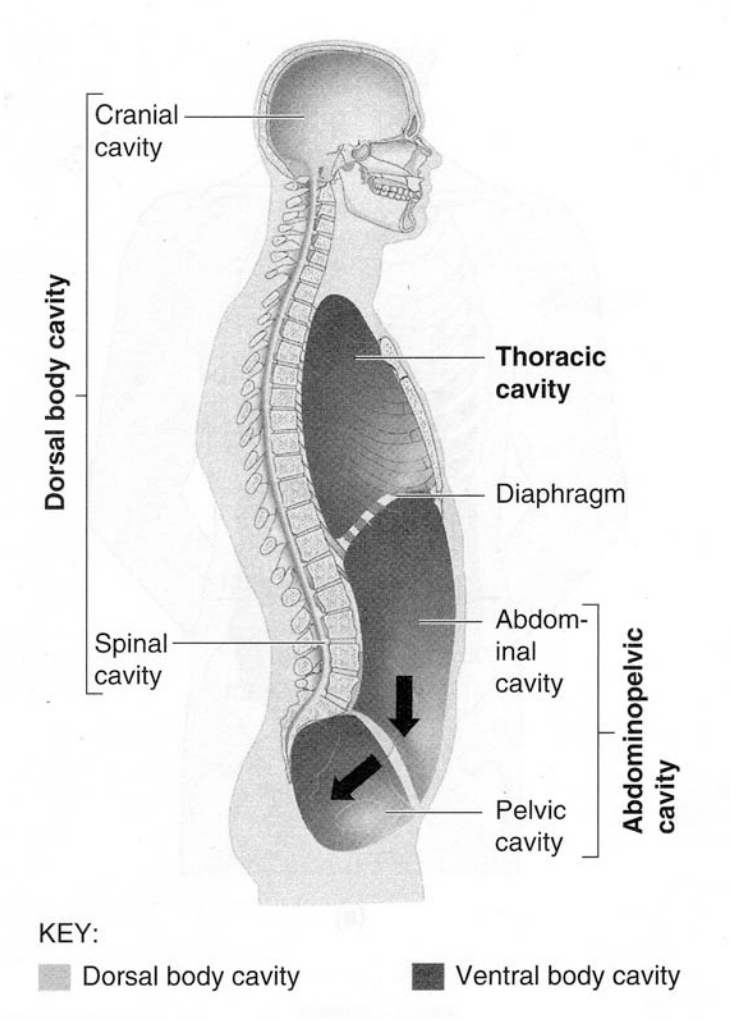

Figure 5. Body cavities

Abdominopelvic Quadrants and Regions

The abdominopelvic cavity is quite large and contains many organs, so it is helpful to divide it up into smaller areas for study. The medical scheme divides the abdominal surface (and the abdominopelvic cavity deep to it) into four approximately equal regions called **quadrants**, named according to their relative position-they are, *right upper quadrant, right lower quadrant, left upper quadrant,* and *left lower quadrant* (Figure 6).

Another scheme, commonly used by anatomists, divides the abdominal surface and abdominopelvic cavity into nine separate regions by four planes, also shown in Figure 6. Although the names of these nine regions are unfamiliar to you now, with a little patience and study, they will become easier to remember. These regions are:

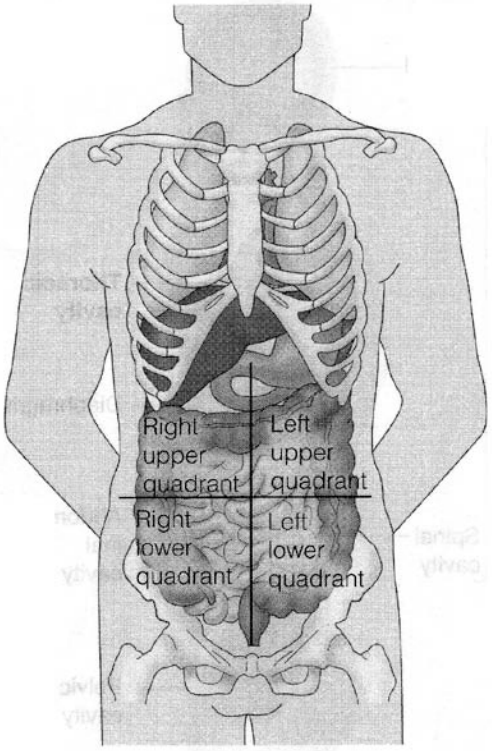

(a)

Umbilical region: The centermost region, which includes the umbilicus.

Epigastric region: Immediately superior to the umbilical region; overlies most of the stomach.

Hypogastric (pubic) region: Immediately inferior to the umbilical region; encompasses the pubic area.

Iliac regions: Lateral to the hypogastric region and overlying the superior parts of the hip bones.

Lumbar regions: Between the ribs and the flaring portions of the hip bones; lateral to the umbilical region.

Hypochondriac regions: Flanking the epigastric region laterally and overlying the lower ribs.

Read through the descriptions of these nine regions locate them in Figure 6. Be sure to notice the organs they contain.

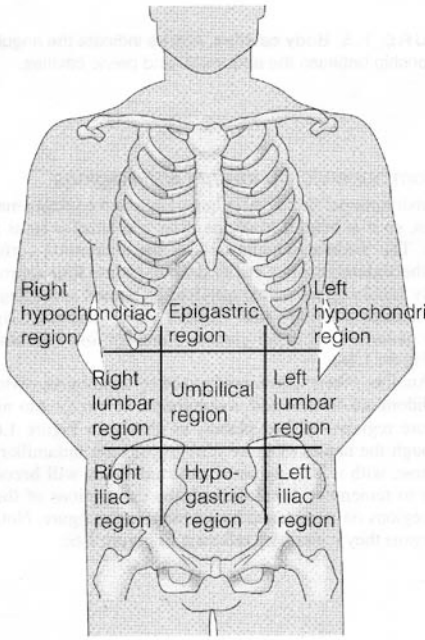

(b)

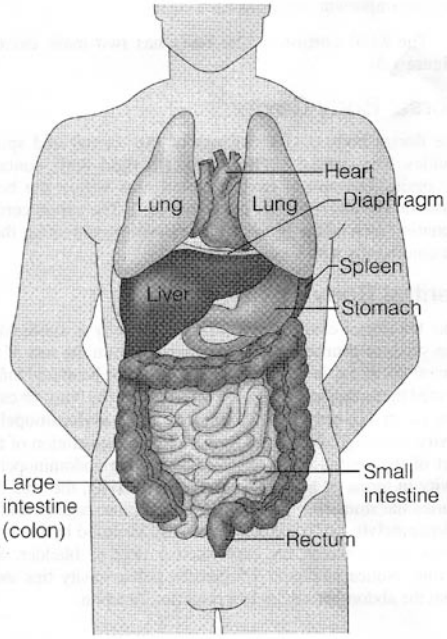

(c)

Figure 6. Abdominopelvic surface and cavity.

Locate the regions of the abdominal surface on a torso model and on yourself before continuing.

Looking at Two Dimensional and Three Dimensional Morphology

Creating Serial Sections

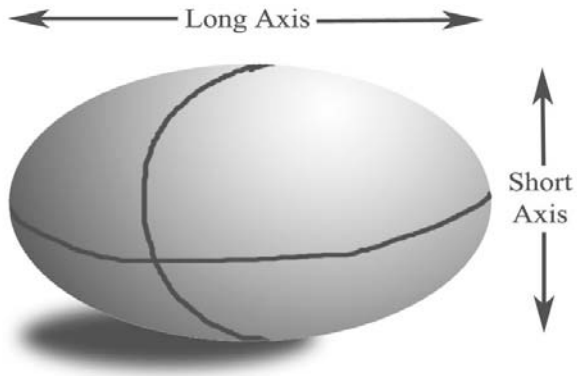

Figure 7. Long and short axis and meridian marks on hardboiled egg

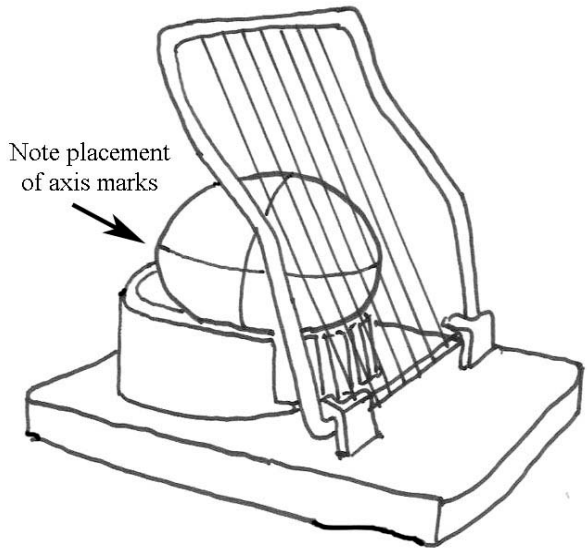

Figure 8. Hard-boiled egg in slicer along long axis

1. Obtain a hardboiled egg and remove the shell from the egg.

2. Using a paper towel, dry the shelled egg. Mark the short and long axis meridians using a Flair (water soluble) type marker (Fig. 7)
3. Using the egg slicer, slice egg along its long axis (Fig. 8).
4. Arrange egg slices in order on a piece of paper (Fig. 9). You should create about 6 to 7 slices.
5. Place grid on the first slice and align axis marks with the x and y axis (0,0)
6. Draw the pattern seen in section one on the serial section grid labeled "Section One" on Figure 9. Please think about this: Seven slices should result in 6 serial sections.
7. Continue for each of the other serial sections. Keep the sections in order; label each in sequence.

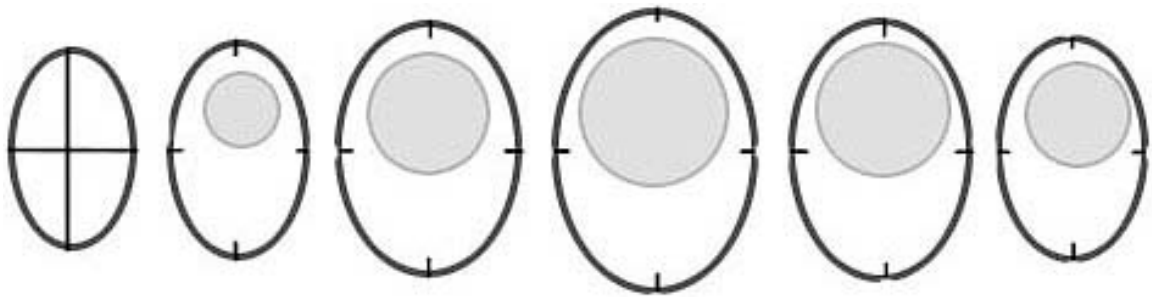

Figure 9. Serial section arranged in order showing axis meridian marks

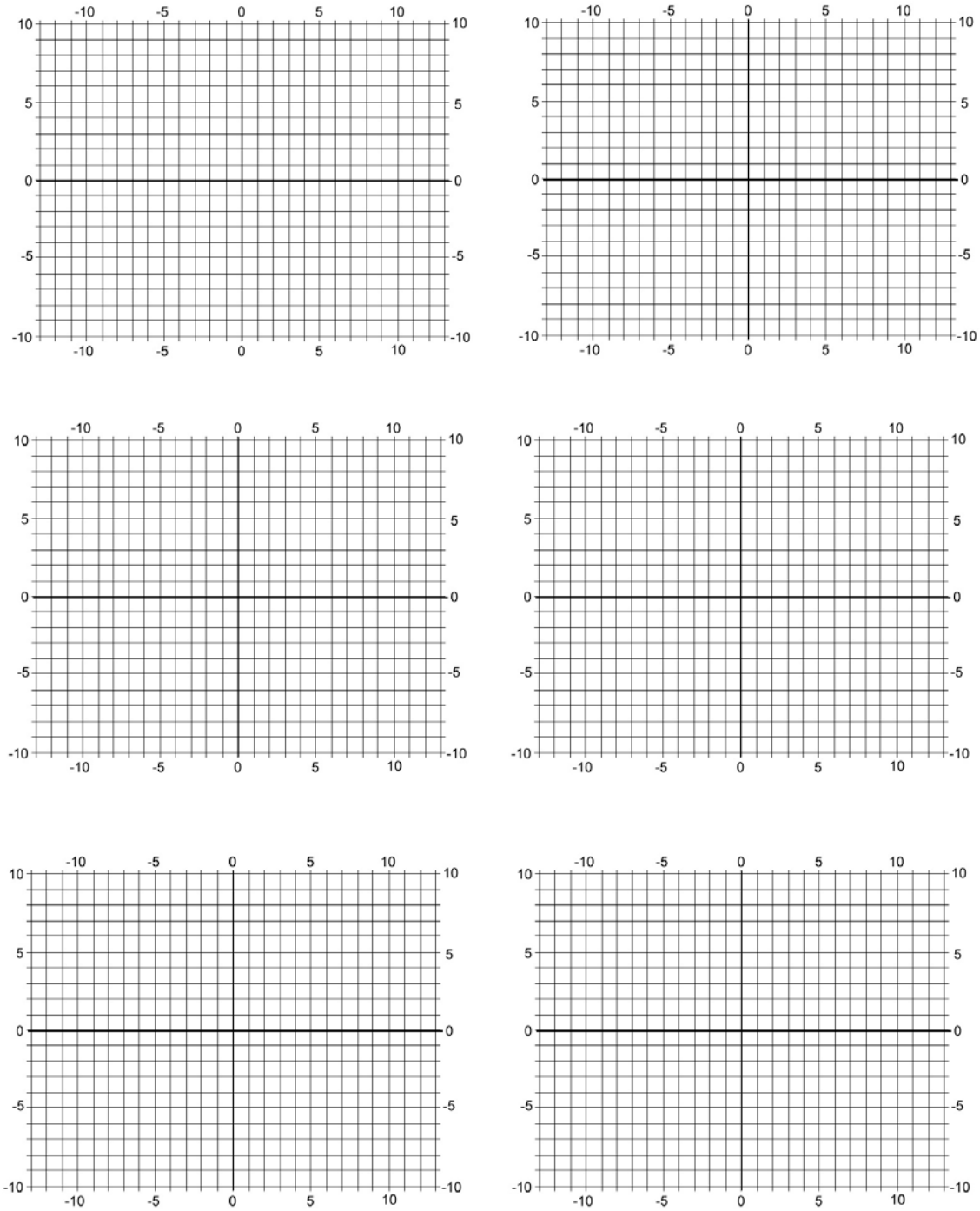

Figure 10. Serial sections through hardboiled egg

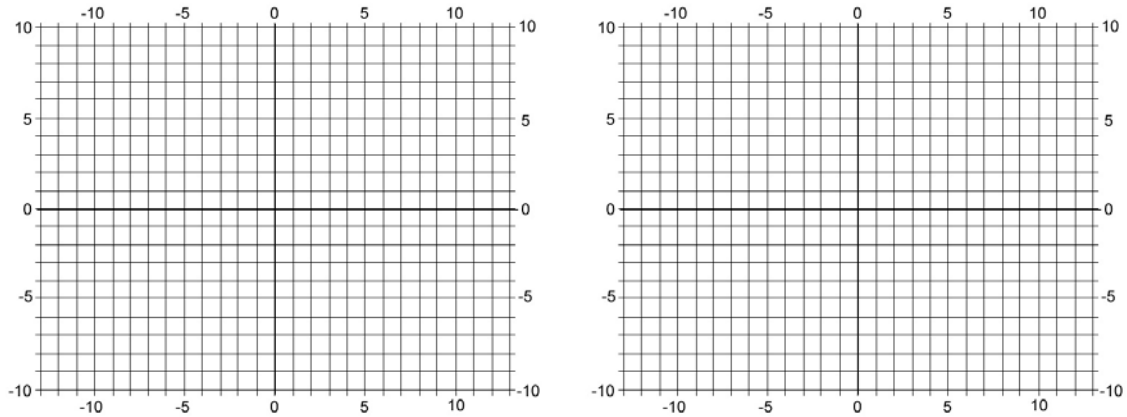

Figure 11. Serial sections through hardboiled egg (continued)

Visualizing a section in the 90 degree plane: Reconstruction

The sections you have just drawn are in a plane known as longitudinal. You will now use these sections to create a cross section. For this assignment you should choose a plane crossing each of your sections in which there is some of the egg yolk present. For instance, suppose you are going to draw the cross section at grid line 5 as shown in Figure 12. From each section at grid line 5 you would transfer the data to that section line in Figure 12. When you are done, you smoothly connect the dots and reconstruct the unknown cross section. Try this with your serial sections and reconstruct a 90 degree cross section in Figure 10.

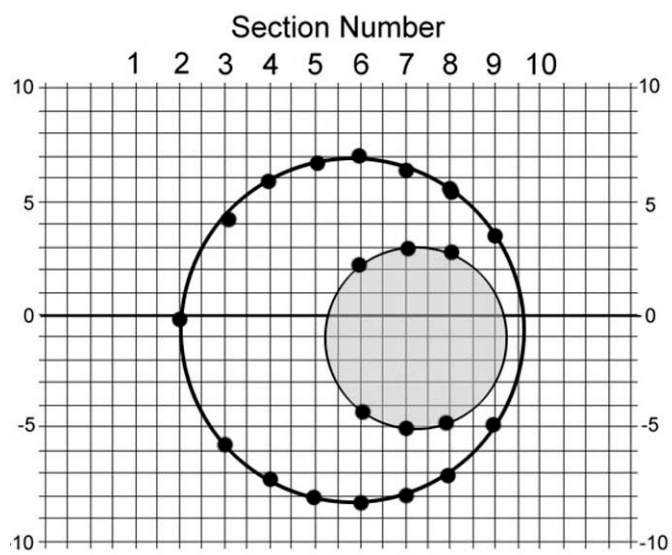

Figure 12. Reconstruction of 90 degree cross section from serial section data. Dots are data from single serial sections.

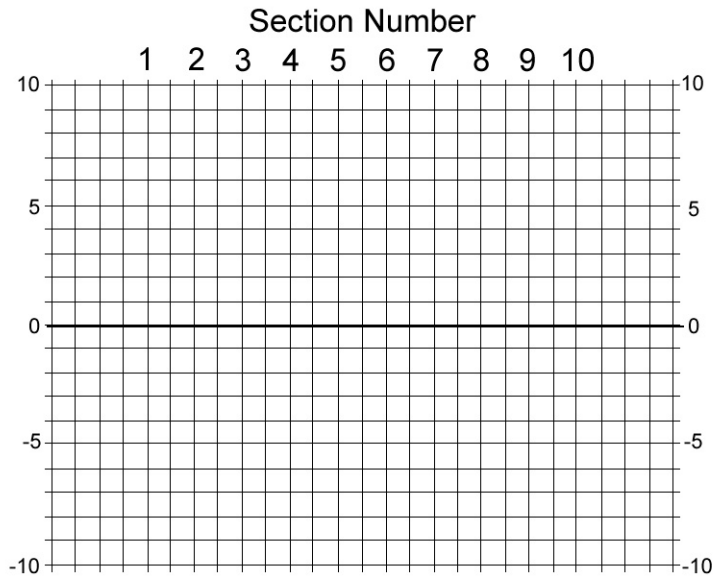

Figure 13. Reconstruction of 90 degree cross section of hardboiled egg